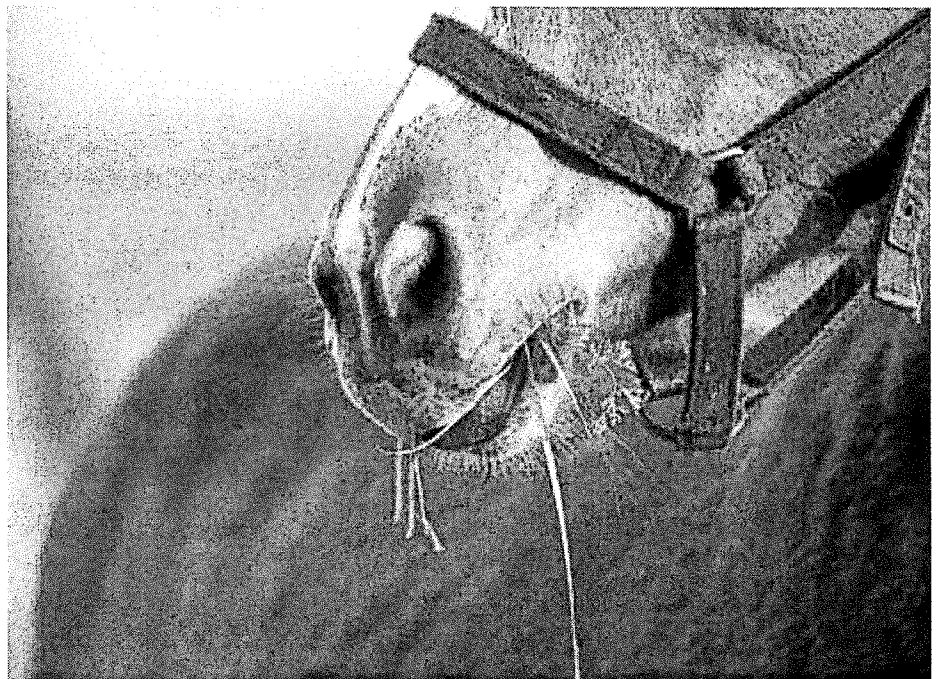


Equine Dentistry: It's Not Just Floating Anymore

Good dental health is vital to your horse's overall well being. As it is for humans and other mammals, oral health cannot be separated from the health of the rest of the body. Years ago, it was not uncommon for people to lose their teeth by middle age. All that changed as we learned more about medicine and health, developed fluoride and healthier lifestyles, and sought regular dental care. The fact is that dental diseases are almost entirely preventable in all species.

In dogs and cats, periodontal diseases are the number one diagnosed problem, and oral infectious diseases are known as "the silent killers." Veterinarians have long promoted regular dental care to prevent the potentially serious problems associated with infections of the gum and chronic oral discomfort.



INSIDE THIS ISSUE...

| | |
|---|----|
| Equine Dentistry: It's Not Just Floating Anymore..... | 1 |
| Guest Practitioner's Message .. | 2 |
| Who Should Care For Your Horse's Teeth? | 5 |
| Equine Internal Medicine and Dentistry Service | 9 |
| New Assistant Director of the CEH | 10 |
| Dillon: The Well-Cared-For But Neglected Horse..... | 11 |

Because many advances have been made in equine health, horses today live well into their twenties and thirties, making it even more important to provide their teeth with regular preventive care. Small problems that are recognized and corrected at an early age seldom become the large problems seen in many of today's adult horses.


Current research is showing that equine teeth that function normally and have normal grinding patterns actually wear more slowly and therefore last longer. This means that the better a horse's teeth are maintained, the longer his teeth will remain effective for grinding long-

stemmed roughage, the staple of the equine diet.

Good dental health is essential to the proper functioning of your horse's digestive system. Because digestion is a complex process that begins with chewing and mixing of food with saliva, horses depend on the ability to chew properly. To do this, their teeth and gums must be in good working order. If the food is not properly chewed, it will not digest properly and could lead to

— *Continued on page 3*

GUEST PRACTITIONER'S MESSAGE



Dr. Travis Henry

Promoting Oral Health in Horses through Modern Equine Dentistry

This idea of lay people performing dentistry versus the veterinarian is a modern day debate. If we look at history, the veterinary community lacked the interest in equine dentistry for many years while several groups

UC Davis to perform modern equine dentistry. We have only scratched the surface for what is to come in equine dentistry. The opportunity to be part of the Dentistry and Oral Surgery service at UC Davis is bringing

The practice of modern equine dentistry requires a physical exam of the entire patient, sedation, and specialized instrumentation to perform the oral exam.

For centuries, people who owned horses knew the importance of caring for their animals' teeth.

Historically, the better the horse's dentition, the more the horse was worth. This scenario caused certain people that were buying and selling horses to be less than honest with a procedure called "bishoping" the teeth. This was a procedure to adjust the horse's dentition to make them appear younger. If we fast forward to today, we do not incorporate the dental health of the horse into their price or worth. We have classically examined their teeth to see if they are "sharp" and need filing. Filing the horse's teeth, or correcting malocclusions is important, but it is only a small component of modern equine dentistry.

The oral exam in other species includes five components. Why do we leave out the other four components in equine dentistry? The answer that makes the most sense is that as horses fell in numbers, we did not embrace dentistry as a part of practice as veterinarians. Equine dentistry was left up to lay people who passed their knowledge on to each other in informal settings.

of lay people were actively providing the service of occlusal adjustments or floating in the equine industry. The practice of equine dentistry requires a physical exam of the entire patient, sedation, and specialized instrumentation to perform the oral exam. The process of administering sedation and formulating a diagnosis legally requires the services of a veterinarian. In some states, they may be able to perform the "float" or occlusal adjustment, but this is only a small component of the horse's oral health. Veterinarians need to equip themselves with the knowledge and instrumentation to provide modern equine dentistry to their patients.

I have had a wonderful career of more than 18 years in practice. One of the most enjoyable experiences has been witnessing the change in equine dentistry from "teeth floating" to a comprehensive exam followed by evidence-based procedures that promote the oral health of the horse. My goal is to be part of the process of training veterinary graduates from

forth many new ways to approach pathological conditions in the horse's mouth. With ongoing research and study of certain conditions, we will continue to refine treatments for our equine patients.

Dr. Travis Henry graduated from the Michigan State College of Veterinary Medicine in 1993 and has been a practicing veterinarian for 17 years. He has had a long-standing interest in equine dentistry and oral surgery and has completed specialized training in these areas. Since 2003, he has owned and operated Midwest Equine Services in Elkhorn, WI, which is dedicated to providing veterinary dental care for horses in the midwest. Dr. Henry is currently a Fellow in the Oral Surgery and Dentistry Service at the UC Davis Veterinary Medical Teaching Hospital, where he treats patients one week each month.

Equine Dentistry
 — Continued from page 1

chronic colic, choke, weight loss and nutritional deficiencies.

Over time, oral problems such as infections of the teeth roots can arise, and pain or discomfort with the bit can influence athletic performance. Many horse owners, and even experienced performance horse trainers, fail to relate behavioral or performance problems with dental malocclusions. A horse that is in pain will not perform to its full potential. Tail wringing, head tossing, fussing with the bit, running backwards, rearing, unexplained switching to right brain (temper fits) can all be dental-related. There are a hundred reasons to maintain your horse's dental health, not the least of which is that it can be painful for him to live with the effects of dental neglect.

Because not all dental problems in horses are obvious to the untrained eye or are revealed through clinical signs, it is important to have regular, comprehensive dental exams conducted by a veterinarian. Often there are no obvious outward signs of disease until the condition is very advanced.

Dr. Mary DeLorey, a veterinarian dedicated exclusively to equine dentistry (Northwest Equine Dentistry, WA), states that, "One of the most important concepts horse owners can embrace is that prevention is the absolute key to good equine dental health. The idea that a horse doesn't need dental attention until he is in middle age must disappear.... Once your horse has reached the age of 6 years, all his permanent teeth are in position and use. If your horse has had periodic, comprehensive dental care up to this time and has no severe malocclusions or dental disease, he's

well poised for lifelong dental health. He should receive maintenance every 8-12 months."

"Horses that are in demanding competition, have heightened sensitivity or pre-existing dental abnormalities may need routine attention more frequently, perhaps every 6 months, to maintain dental health and comfort. Each horse is an individual with unique needs. A veterinarian skilled in equine dentistry can work with you to determine a schedule most appropriate for your horse."

Equine dental care has experienced a resurgence of interest and is becoming emphasized as an integral part of veterinary college curricula. A veterinarian well-trained in equine dentistry has the skills to prevent most, if not all, major dental problems that previously have been accepted as an inevitable part of aging.

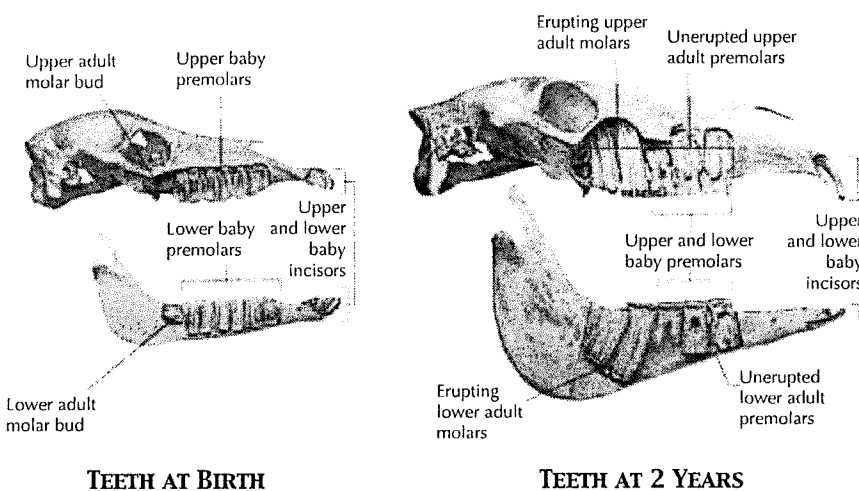
Equine Teeth

Like humans, horses develop two sets of teeth in their lifetime: the deciduous teeth and the permanent teeth. The deciduous teeth or caps are comprised of milk incisors and premolars. The last of the deciduous teeth erupt at around 6 months of age and begin to be replaced by adult teeth around age 2-1/2. By age 5, most horses have their full complement of permanent teeth.

An adult male horse has up to 44 permanent teeth including the canines, while a mare may have between 36-44 (mares do not usually have canines). The teeth are hypsodont dentition, meaning that they are characterized by high-crowned teeth and enamel that extends past the gum line. This provides extra material for wear and tear. Some examples of animals with hypsodont dentition are cows, horses, deer and other animals that feed on gritty, fibrous material. The teeth are oriented in an anisognathous fashion, where the maxillary (upper jaw) quadrants are wider than their mandibular (lower jaw) counterparts. This configuration allows for effective grinding but produces sharp edges over time.

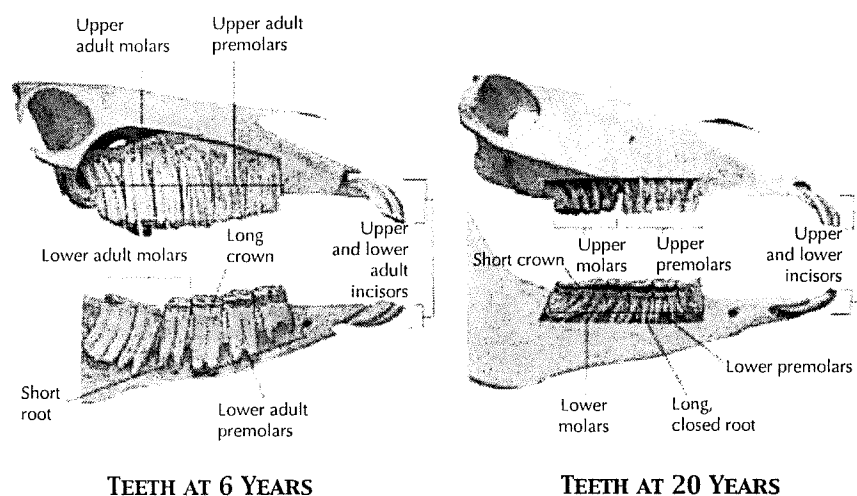
The following illustrations show the development of teeth in horses at birth, at 2 years, 6 years and 20 years.

— Continued on page 5

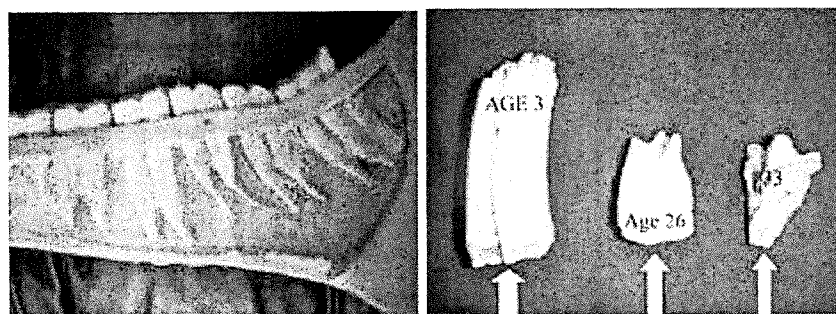


Equine Dentistry

— Continued from page 3



The initial length of the permanent equine teeth (crown and root combined) is about 4 inches. The reserve crown and roots are deeply embedded in the jawbone, as shown in the photo below. Teeth continue to erupt throughout a horse's lifetime and are worn down primarily by chewing. As seen in the next photo, the length of tooth diminishes significantly as the horse ages. A 5-year-old horse's head weighs significantly more than that of a 20-year-old horse.



The Dental Exam

For years, the equine oral exam has been a routine procedure in veterinary practice to determine whether the horse's teeth needed "floating". Because of the characteristics of the teeth (described above) combined with a table angle that slopes to the buccal surface, the cheek teeth tend to form prominent sharp enamel points. The incisors and cheek teeth are also constantly erupting to replace worn teeth, and when appropriate anatomy is not present, opposing teeth will produce overgrowths. Historically, the oral exam has been aimed at identifying these abnormalities of the teeth and correcting them primarily by floating the teeth.

However, this approach limits the focus to only occlusion-related abnormalities and does not address the health status of other parts of the mouth and head,

including the gums, tooth root, dental pulp and surrounding tissues—all vital to overall dental health. A proper dental exam should include inspection all of these structures, as described below.

An external examination of the head is comprised of evaluating the muscles used for chewing to determine the existence of any atrophy, evaluating head symmetry, and any bony or soft tissue swelling. This exam should be performed on the unsedated horse. Muscle atrophy can be related to several clinical diseases as well as dentistry. Dental-related pain can limit the use of the appropriate chewing muscles and cause loss of the musculature on the underused side.

Pain associated with these muscles and of the temporomandibular joint should also be noted via palpation. The symmetry of the head related to any abnormal protrusion or twisting of the upper or lower jaw will contribute to overgrowths of the incisors and the cheek teeth. Bony swellings are often seen with dental disease. Thus, all of these external findings will contribute to the internal examination of the mouth. Once the external exam is complete, the horse is sedated and an exam of the incisors is performed before the oral speculum is placed in the mouth.

The oral soft tissues include the gingiva, mucosa, tongue and hard/soft palate. The gingiva should be tight in approximation of the tooth and light pink in color. Loss or recession of the gingiva and an increased redness indicate gingivitis. The mucosa of the lips, cheeks, and lingual surfaces, as well as tongue and hard/soft palate should be light pink in color and devoid of abrasions. Abrasions that are commonly noted are due mostly to

sharp enamel points formed during chewing. Examination of these tissues will allow early detection of periodontal disease and oral neoplasia.

Occlusion (the grinding function of the teeth when the jaws are brought together) is often observed during the external oral exam and re-evaluated during the internal exam. This would include the identification of incisor and cheek teeth occlusion and evaluation of movement and range of motion. Missing teeth or the presence of extra teeth should be noted as well as any associated overgrowth that might affect occlusion.

The table angle of the cheek teeth and the level of staining should also be noted. (The table angles should be identical on gross examination.) An increase in color staining indicates a lack of occlusion attrition or chewing resulting in the buildup of tannic acid staining from food materials. (Occlusion attrition is the normal wearing away of the tooth during chewing.) The increase of a table angle on one side of the mouth indicates a lack of attrition or a functional inability to use these quadrants. The horse will give us subtle signs of their pathology before they will present with problems eating.

Periodontal status (gums and other tissue surrounding the teeth) is examined by noting anywhere in the mouth where food is caught and stagnating. Periodontal disease in the horse often begins with food packing in the interdental spaces, leading to rotting feed, acid production, and bacteria that contribute to inflammation of the periodontal structures. This is a painful condition in the horse and is cause for quidding. Early detection, radiographs, and appropriate occlusal adjustment are the best approaches to treatment.

Endodontic status is evaluated by noting any defects in the occlusal dentin of the pulp horns. The equine tooth is comprised of pulp horns that have live pulp extending from the apice at the common pulp chamber toward the occlusal surface. The function of the pulp is to produce primary, secondary and tertiary dentin. Primary dentin is present in the pulp horns when the teeth enter the mouth. Secondary and tertiary dentin are produced while the teeth are being worn away. Without the ability to efficiently produce dentin, the pulp would become exposed and result in pulpitis (infection of the dental pulp).

Each chewing surface should be closely examined to identify any decay of the dentin in the pulp horns. Depending on the severity of decay, cavities in these structures can cause apical infection and fracture of the clinical crown, reserve crown and root.

In summary, the equine oral exam is a comprehensive exam that should be carried out with diligence. When any type of disease is noted, imaging of the reserve crown and roots should be done to evaluate the severity. In many species, full-mouth radiographs are used in each exam. Equine practice is becoming more proficient at this due to digital imaging modalities. However, far too many oral exams are still not being followed with imaging, which can lead to improper diagnosis and failure of the treatment plan.

A thorough dental exam should include keeping dental records. Knowing a horse's dental history can be important if you move or change veterinarians or if you decide to sell your horse.

The equine oral exam should be completed with every routine dental check up and occlusal adjustment.

It does not require expensive instrumentation, but it does require an understanding of basic dental anatomy and the desire to perform the exam.

— Continued on page 7

Who Should Care for Your Horse's Teeth?


Dental health should be addressed by a licensed veterinarian. In many states it is illegal for non-veterinarians to perform equine dental procedures. In states that do permit trained dental technicians to perform dental procedures, such individuals *must* work alongside a licensed veterinarian.

The American Association of Equine Practitioners also supports this but cautions that *the practice of equine dentistry is an integral branch of equine veterinary medicine.... Any surgical procedure of the head or oral cavity; the administration or prescription of sedatives, tranquilizers, analgesics or anesthetics; procedures which are invasive of the tissues to the oral cavity including, but not limited to, removal of sharp enamel projections, treatment of malocclusions of premolars, molars, and incisors, reshaping of canine teeth, the extraction of the first premolars and deciduous premolars and incisors; treatment, extraction or repair of damaged or diseased teeth; periodont treatment; and dental radiography are veterinary medical procedures and should be performed by a licensed veterinarian.*

Equine Dentistry — Continued from page 5

Common Dental Problems

Horses grind their food using a side-to-side movement of the lower quadrants of teeth against the upper arcade, known as lateral excursion. Consequently, an important part of equine dental care is to maintain good alignment at the three critical points shown in the following photograph so that the horse can chew its food properly. Since equine teeth erupt throughout a horse's lifetime and wear down in many different ways depending on the individual animal, teeth can rapidly become uneven and alter the alignment of the mouth. A critical part of regular dental care is to keep all the teeth relatively even in length and prevent minor problems from becoming major problems. An overgrown tooth is likely to damage its opposing tooth, which can lead to decline or infection.



The red arrows show the three points of alignment: the temporomandibular joint at the top, the cheek teeth (molars and premolars) in the middle, and the incisors at the front.

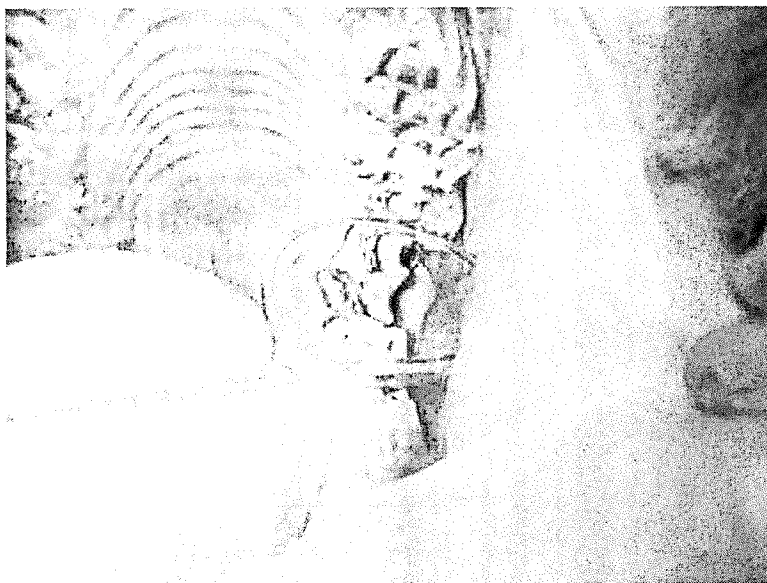
Maintaining an even bite plane during a horse's middle teens is especially important to ensure a level grinding surface when the horse is in its twenties. If an even bite plane is neglected, it may be impossible to achieve alignment when the horse is older, since the teeth will wear unevenly and eventually stop erupting. Again, the goal of regular,

consistent dental care is to prevent minor problems from becoming major ones that can impact the quality of an animal's life, particularly in its later years.

Some common problems that may be addressed during regular maintenance include:

- Sharp enamel points forming on cheek teeth, causing lacerations or abrasions on the cheeks or tongue.
- Retained caps (deciduous teeth that are not shed).
- Discomfort caused by bit contact with the wolf teeth (small vestigial premolars).
- Hooks and ramps forming on the first upper and last lower cheek teeth.
- Pulpitis or endodontic exposure like occlusal pulp horn exposure.
- Lost and/or broken teeth.
- Abnormally long teeth.
- Infected teeth and/or gums.
- Misalignment of the mouth/poor apposition (can be due to congenital defects or injury).
- Periodontal pocketing of feed and other evidence of periodontal (gum) disease.


The following photographs show some dental problems identified during the course of a thorough exam.




This photo shows exposed pulp horns and fracture of the crown on the cheek surface of the tooth. Approximately 25% of the tooth is missing.



Example of calculus buildup of the canines.



Draining tract on the cheek side of the tooth from an infection of the tooth root.

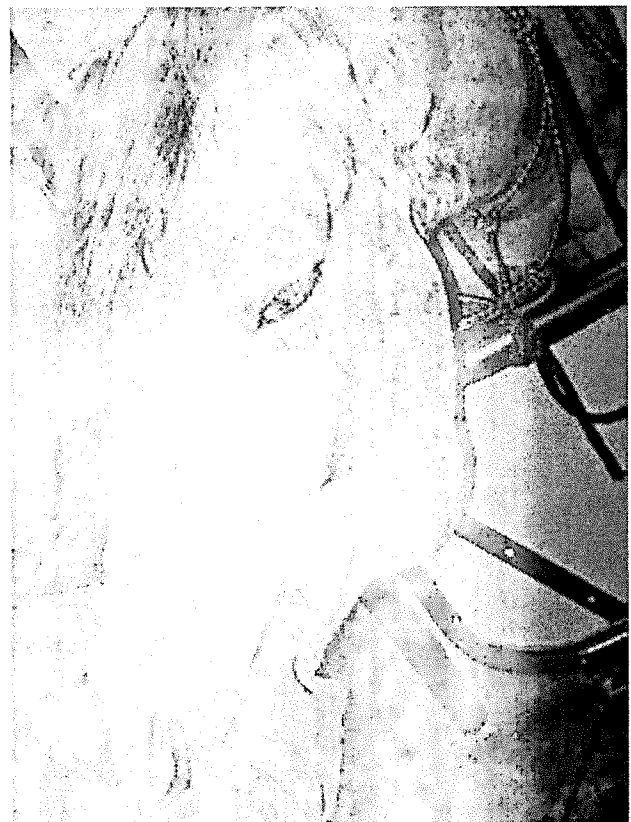

Fracture of an incisor. Note bleeding from the live pulp of the tooth.

though not always indicative of dental problems, can alert you to a potential problem:

- Loss of feed from mouth while eating (quidding), difficulty chewing or excessive salivation.
- Loss of body condition, weight loss.
- Large or undigested feed particles (long stems or whole grain) in manure.
- Head tilting or tossing, bit chewing, tongue lolling, fighting the bit or resisting bridling.
- Poor performance such as lugging on the bridle, failing to turn or stop, even bucking.
- Refusing to take a lead.
- Foul odor from mouth or nostrils or traces of blood from the mouth.
- Nasal discharge or swelling of the face, jaw or mouth tissues.

— Continued on page 8



Bony swelling of any kind on the face warrants an oral exam.


Horses with dental problems may show signs of pain or irritation, or they may show no signs at all. If a horse starts behaving abnormally, dental problems should be considered as a potential cause. The following signs,

Equine Dentistry
 — Continued from page 7


If you are diligent about caring for your horse's teeth, chances are you will not be surprised by a sudden problem. Oral exams should be an essential part of an annual physical examination by a veterinarian. The end result is a healthier, more comfortable horse and teeth that may sustain the horse well into old age.

Dental Problems in Older Horses

Older horses can be more susceptible to infections, gum problems and broken or lost teeth. Horses with Cushing's disease are especially prone to oral infections. Horses that are 20 years old and older should have their teeth examined at least once a year (and preferably twice a year) to prevent any serious problems. An aging horse that can chew its food properly will be more inclined to have good nutrition, be less susceptible to colic or choke, and maintain good body condition. 38



The idea of the horse dental dental attention will be in the dental as appear to be and it is joined in axis can be brought an mitigated early on.



The dental chart is an important part of the medical record for any equine dental patient. The classic dental charts did not adequately document the five components of the oral exam, a treatment plan, and any complications experienced.

A new dental chart, shown below, was developed by Dr. Molly Rice of Midwest Equine Services, Elkhorn, WI. It incorporates all of the components of the oral exam in a systematic fashion. The chart allows the record-keeping to be done as if you were looking in the oral cavity of the horse, thus dividing the findings into four quadrants and reducing the chance of leaving out a finding or mislabeling it.