



## Back Country Medicine TABLE OF CONTENTS

INTRODUCTION: MEDICAL DECISION MAKING.....	2
WILDERNESS WOUND MANAGEMENT.....	3
BURNS.....	5
SPRAINS, DISLOCATIONS, AND FRACTURES.....	6
HYPOTHERMIA.....	8
WILDERNESS DENTAL EMERGENCIES.....	11
WILDERNESS TRAUMA EMERGENCIES.....	12
TRANSPORT OF VICTIMS.....	27
MEDICAL KITS.....	35
IMPROVISING TOOLS FOR MEDICAL EMERGENCIES...	36

## **INTRODUCTION: MEDICAL DECISION MAKING**

In its current incarnation the following information represents eleven articles that have appeared in the Squaw Butte Backcountry Horsemen monthly chapter newsletter. These articles are the result of my attendance of the Rocky Mountain Wilderness Medicine Conference held at Boise State University June 21-24, 2004. My registration was paid by the education fund of the Back Country Horsemen of Idaho. Sources for the information presented here include the course syllabus, the Idaho Mountain Search and Rescue webpage, and the textbook Wilderness Medicine, Paul S. Auerbach, M.D., ed, CV Mosby & Co, St. Louis, MO, 2001 (with editors permission).

The material presented here is meant to help guide medical decision making in the backcountry. The information falls into three categories. The first category includes information useful for treating injuries that are appropriately handled by non-medical personnel without technical backup. The second category includes conditions which require technical backup and are indications for immediate evacuation. The third category includes improvisation techniques that can be applied while waiting for or arranging evacuation. While some of this seems like plain common sense, it is easier to use your common sense with some forethought and planning.

The first rule when traveling in the backcountry, is to be aware of the closest evacuation station. Always carry your personal medical kit; this includes your car key and communications devices (cell phone and radio). The group designated medical officer (MO) should carry a group kit and additional tools for evaluation such as a stethoscope and medications (see section on medical kits).

When an injury occurs, the victim and the MO should be given quiet time to assess 1) level of pain 2) location of injury 3) impairment resulting from injury 4) need for outside medical care versus in camp care and 5) feasibility of travel for outside care. MO will report to the trail boss. Tasks to be designated by the trail boss include 1) in camp care with setting up an aid station 2) evacuation of victim by group and 3) sending riders for medical evacuation while providing comfort care in camp aid station.

## WILDERNESS WOUND MANAGEMENT

When wounds and lacerations occur in the wilderness setting without associated traumatic injuries, the steps of treatment are as follows: control bleeding, examine the wound, initiate treatment to minimize infection, and close the wound if this can be done without increasing the chance of infection.

The vast majority of bleeding will be controlled with direct pressure, applying the most sterile covering available. Applying pressure over major arterial pressure points is discouraged, as is the use of tourniquets. In the event of bleeding that can not be controlled by direct pressure, tourniquets may be applied - with the knowledge that limb sacrifice is possible. If applied, tourniquets should be released every 5 to 10 minutes if possible to transiently restore blood flow to the limb.

In examining the wound it is important to remember that lacerations are often the most obvious sign of trauma; however, skin injuries are rarely life-threatening. Contusions, abrasions, and lacerations signal the examiner to focus on areas of potential deeper injury. Contusions often overlie extremity fractures or, when present on the trunk, suggest possible underlying organ damage. Extremity lacerations may be associated with fractures or may extend into joints. In deciding to close a wound or pack it open, take into account the mechanism of injury, age of the wound, site of the wound, degree of contamination, and ability to effectively clean the wound.

Infection is often more dangerous than the wound itself. This is minimized by tetanus immunization, cleaning the wound thoroughly by irrigation with removal of foreign objects, cutting away dead tissue, and giving antibiotics for high-risk wounds. Anyone visiting the backcountry should have a current tetanus immunization. The main problem faced in the wilderness is access to adequate supplies. Irrigating the wound with a forceful stream is the most effective method of reducing bacteria and removing dirt. The cleansing solution is directed into the wound from a distance of 1 to 2 inches at an angle perpendicular to the wound. The amount of irrigation fluid varies with the size and contamination of the wound, but should average no less than 8 oz. Improvised wound irrigation can be done with a container that can be punctured, such as a sandwich or garbage bag, and a safety pin or 18-gauge needle. Fill the bag with water that is disinfected with iodine tablets, filtering or boiling (or tap water). Two teaspoons of salt in one quart of water makes an appropriate salt solution. The water is squeezed forcefully through the puncture hole in the bag to cleanse the wound.

Sutures, staples, tape, pins, or glue can be used to close wounds. Although suturing is still the most widely used technique, stapling, taping, and gluing are ideal methods for closing wounds in the wilderness. Topical anesthetics either in solution applied to the wound or injected into the surrounding skin should be used for suturing and stapling. Stapling can be done if the device is available. To tape a laceration it first needs to be dry and not bleeding. Tape should be cut to ¼-inch or ½-inch widths, depending on the size of the laceration, and to a length that allows one inch of overlap on each side of the wound. After applying tape to one edge the opposite side of the wound is pushed and taped. Space between the tapes (about 1/8 inch) allows the wound to drain. Wound taping does not work well over joints or on hairy skin surfaces unless the hair is first removed.

If there is a bleeding scalp laceration and the injured person has a healthy head of hair, you can tie the wound closed using the victim's own hair and a piece of suture, dental floss, sewing thread or thin string. Take the material and lay it on top of and parallel to the wound. Twirl a few strands of hair on each side of the wound and then cross them over the wound in opposite directions so that the force pulls the wound edges together. Have an assistant tie the strands of hair together with the material while you hold the wound closed with the strands of hair. A square knot works best. Repeat this technique as many times as necessary, along the length of the wound, to close the laceration.

Tissue glue is ideal for backcountry use because it does not require topical anesthesia, is easy to use, reduces the risk of needle stick injury, and takes up much less room than a conventional suture kit. The U.S. Food and Drug Administration (FDA) has approved a topical skin adhesive to repair skin lacerations. Dermabond is packaged in a small single-use applicator and costs about \$30 per tube. Paint the tissue glue over the apposed wound edges using a very light brushing motion of the applicator tip. Avoid excess pressure of the applicator on the tissue because this could separate the skin edges, forcing glue into the wound. Apply multiple thin layers (at least three), allowing the glue to dry between each application (about 2 minutes). Deeper wounds should not be filled, but each tissue layer closed in succession.

Wounds should be covered with a sterile, breathable dressing to keep additional dirt out of the repair. Most lacerations can be dealt with in the backcountry and do not require evacuation. Injuries of the hands or feet that may involve tendons, however, should be examined by an orthopedic surgeon or veterinarian within 3-5 days. Remember, these principles of wound care are for you and the horse you rode in on.

## BURNS

The severity of a burn injury is judged by the cause of the burn, the size and depth of the burn, and the body part that is burned. Scalds and contact burns can occur readily in a camp setting. Other camp related burns can occur from cooking with white gas, lanterns in tents, and starting or improving campfires with liquid fuels. Wood fuel stoves in tents present special smoke and fire risks.

General Treatment:

1. Remove burned clothing
2. Assess for smoke inhalation injury
3. Treat small burns with cool water taking care not to cause hypothermia (ice packs should be applied no longer than 10 minutes)
4. Remove jewelry from burn and areas below them
5. Flush chemical burns with large amounts of water

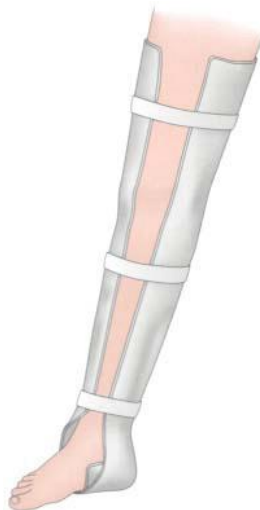
Burns that require evacuation include the following: 1<sup>st</sup> and 2<sup>nd</sup> degree burns that cover more than 25% of the body surface area (BSA), the area of the victim's palm is equivalent to 1% BSA; deep 2<sup>nd</sup> 3<sup>rd</sup> degree burns over more than 10% BSA; deep burns of the face, hand, foot, or naughty bits; and burns involving smoke inhalation injury. Smoke inhalation is a progressive lung injury indicated by the presence of burns of the face or mouth, singed nasal hair, soot in the mouth or being coughed up, hoarseness or noisy breathing, difficulty breathing, drooling or difficulty swallowing, swollen tongue, and agitation. If evacuation will take longer than 30 minutes an oral balanced salt solution is used to avoid dehydration, the victim should be kept warm and the burn area clean.

Minor burns can be treated in the wilderness setting if appropriate supplies are available and wound care is diligent. Treatment starts with cleaning the burn by flushing with water or salt water to remove dirt and dead skin. The next step is to cool the burn with wet compresses or water immersion; ice should not be used directly on skin. Any dead skin should be peeled off or trimmed with a sharp clean knife. Large blisters (greater than 1 inch diameter) should also be trimmed if sterile dressings are available. Small firm blisters should be left alone. An aloe vera gel or lotion should be applied to the burn. Aspirin or ibuprofen (600-800 mg three times a day) should be given. Cortisone type creams are not helpful and sprays with benzocaine may cause allergic reactions. Dry non-adherent dressing should be applied and changed daily. Signs of infection include fever, pus, foul odor, and redness with swelling in the normal skin around the burn. If these are present, antibiotics such as erythromycin are needed.

## SPRAINS, DISLOCATIONS, AND FRACTURES

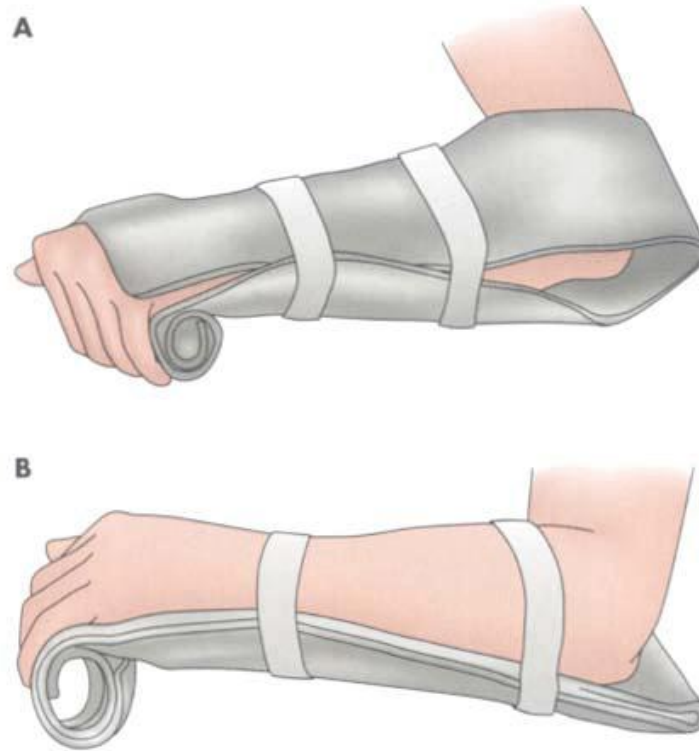
Injury to a limb which involves a dislocation or a fracture usually results in immediate extreme pain and loss of function of the limb. With a bone fracture or a complete disruption of ligaments the victim often reports hearing or feeling a pop or a snap. A visual assessment is first done to compare for loss of symmetry from one side to the other. If there is a visible deformity of the wrist or ankle treatment in the field does not require distinguishing a break from a ligament injury. Three things that must be assessed prior to treatment include joint function, disruption of blood supply resulting from the injury, and nerve function across the area of injury.

Evacuation is recommended for spine injuries, pelvic fracture, open fracture (antibiotics should be given in the field), injury with swelling which compromises blood flow or causes sensory loss, hip or knee dislocation, and laceration of tendons or nerves. In most fractures and dislocations the first principle of treatment is to make the injured limb look like the uninjured limb. Once this has been accomplished, the limb needs to be stabilized with splints to prevent motion. Treatment for pain may be given before alignment once mental status, nerve function, and blood supply are assessed. Below are two examples of how padded aluminum splints can be used.



Lower leg and/or ankle splint. A sugar-tong splint can be used to immobilize fractures of the tibia, fibula, or ankle

© 2005 Sally Schindele, MD



Forearm splints for the treatment of wrist or forearm fractures. The sugar-tong splint (**A**) prevents pronation and supination and has the advantage of greater security and protection than the volar splint (**B**) because of its anterior-posterior construction.

**Auerbach: Wilderness Medicine, 4th ed.,** Copyright © 2001 Mosby, Inc.

## **HYPOTHERMIA**

There are four mechanisms by which warm blooded animals normally lose heat: these include the following: radiation, conduction (increased in water), convection (increased by “wind chill”), evaporation and respiration (affected by humidity and temperature). To prevent hypothermia appropriate garments should be worn to counteract these heat losses. Remember “cotton kills.” When traveling in cold seasons layering is essential. A drying layer which wicks moisture from the skin is worn next to the skin. Next an insulating layer, such as fleece, which can substitute as an external layer is required. The external layer should be wind and water proof. Boots should be appropriate for terrain as well as for horseback, adequately insulated, and with adequate space for thick wool or fleece socks. Gloves or mittens should be adequately insulated and weather proof. Hoods or hats covering the ears are needed.

Preparation for cold weather conditions includes items to be carried specifically for prevention and treatment of hypothermia. The following is recommended by Idaho Mountain Search and Rescue Unit (IMSARU) for a 24 hour pack: extra clothing; a 24 hour food supply with 2 quarts of water, cocoa or tea with sugar; a metal cup and spoon; matches in a waterproof container, candle/other fire starter; tarp, tube tent or bivouac sack, and sleeping pad.

Normal body core temperature is 99.6 degrees Fahrenheit. In mild hypothermia temperatures rang from 91-98 degrees Fahrenheit. Moderate hypothermia is seen at 83-90 degrees Fahrenheit. Severe hypothermia is below 82.4 degrees Fahrenheit.

Normal responses to body cooling include effects on the following organ functions:

1. Heart – mild hypothermia increases pulse and blood pressure, when body temperature drops below 90 degrees these decrease and abnormal rhythms can occur
2. Brain – energy use decreases
3. Lungs – breathing rate increases initially, but below 90 degrees decreases with loss of gag reflex



4. Intestine – movement stops below about 93 degrees
5. Kidney – urine output initially increases due to shunting of blood from extremities to the body core. This results in dehydration.
6. Blood – becomes more concentrated and clotting may be impaired.

Drugs that interfere with heat maintenance include nicotine, alcohol, Aspirin, Tylenol, Ibuprofen and blood pressure medications. Immersion in cold water has the additional problems of cold shock and swimming failure prior to the onset of hypothermia (can take up to 30 minutes after immersion). Cold shock initiates a gasp response which can cause water inhalation. Breathing rate increases so that breath holding becomes more difficult. Pulse and blood pressure can rise. There is a loss of movement in hands and feet. This proceeds to swimming failure with loss of coordination in arms and legs. Breathing and swimming are mismatched.

Signs and Symptoms of Hypothermia:

1. Signs of mild hypothermia (91-98 degrees) include shivering, slurred speech or inability to speak clearly, poor judgment, loss of memory, apathy, loss of coordination, rapid pulse and breathing, hunger, nausea, fatigue and dizziness.
2. Moderate hypothermia (80.6 -89.6 degrees) is characterized by progression to unconsciousness. The shivering response is lost and the victim may paradoxically undress. Pulse and respiratory rate are slowed. Susceptibility to cardiac arrest is increased, pupils are dilated.
3. Severe hypothermia may be difficult to distinguish from death. As the pulse and respirations slow severely it takes longer to detect them.

Treatment for mild hypothermia includes the following measures:

1. Gently remove all wet clothing and replace it with dry clothing.
2. Insulate the victim with sleeping bags, saddle pads, or blankets.
3. Use adequate insulation underneath the victim.
4. If able to swallow, encourage drinking warm sweet beverages (no caffeine).
5. Evacuation is generally not required.

Treatment for moderate hypothermia requires technical support, thus after steps 1-3 above are taken victim should be evacuated. External warming of high circulation areas such as armpits and groin (not extremities) can be done with hot water bottles, chemical packs, or hot rocks. No massage or vigorous warming of extremities should be attempted because of the cardiac excitability. Warming of hands and feet in this circumstance can lead to “after-drop.” This is when body core temperature decreases further because cold blood is returned too quickly to

vital organs, increasing susceptibility to cardiac arrest. If frostbite is also present hypothermia before attempting to re-warm extremities.

With severe hypothermia, CPR is initiated when there is no pulse or respiratory effort. Evacuation needs to be rapid. The victim needs appropriate therapy before a declaration of death is made. The lowest body temperature known to have been survived by an adult is 56.8 degrees.

## WILDERNESS DENTAL EMERGENCIES

The first rule to avoid back country dental problems is *never leave home with a toothache* (see movie Castaway with Tom Hanks). It is also recommended to use the toothbrush and dental floss which you've packed in. Emergencies can arise which include inflammation, infection, and trauma. In order to deal with these, the addition of a small travel exam kit and a temporary filling material to the first aid supplies are helpful. Small, commercially available exam kits will contain a mirror, a light, and a dental explorer. Paste (such as Temparin) is available which can be used to replace crowns, repair lost fillings, or provide a temporary fix after trauma. This contains oil of clove and zinc oxide.

Inflammation or toothache is usually the result of cavity. It is a throbbing pain, worsened by hot or cold liquids or food. It is restricted to one tooth which can be identified by tapping the teeth. Cotton soaked in oil of clove is helpful for pain relief. The temporary filling material can be packed into the cavity. Ibuprofen is also recommended.

Infections can include canker sores, cold sores, and gum abscesses. Canker sores are painful, round, superficial ulcers with a red halo. They usually last for 10 to 14 days. Treatment includes topical steroids. Rinses with tincture of benzoin can be used to control pain. Cold sores are treated with antiviral drugs. Gum abscess is a soft, hot, painful swelling in the gum above a tooth. This requires incision with a clean, sharp knife from the point of maximum swelling down to the bone. The incision needs to be spread to drain all the fluid and a small drain placed. This can be made from a surgical glove or gauze dressing. Warm salt water rinses should be used every two hours. Ice can be applied to the area before incision to aid in pain control.

Trauma can include crown fracture, root fracture, and tooth displacement. With a crown fracture any rough edges should be smoothed with a fingernail file and covered with temporary filling paste. If bleeding is present it can be stopped with a moistened tea bag. With a root fracture the tooth may be out of position. Any mobile fragments are removed and the tooth repositioned. It can be sutured in place through the gum. Teeth that are completely knocked from their socket may be replaced with a good result within 30 to 60 minutes. Clean the tooth with salt water or milk. Stop bleeding with a tea bag and remove and clot with salt water rinses. Slowly and firmly replace the tooth in the socket. It needs to be held in place with suture or a splint. If it can not be replaced immediately it can be stored in salt water or milk.

## WILDERNESS TRAUMA EMERGENCIES

The medical literature is limited regarding the incidence of injury incurred during wilderness-related activities. It is estimated that greater than 10 million Americans participate in wilderness backpacking and camping activities annually. The injury and evacuation patterns recorded by the National Outdoor Leadership School over a 5-year period found that injuries occurred at a rate of 2.3 per 1000 person-days of exposure, with orthopedic and soft tissue injuries most frequent. A study of case incident report files from eight California National Park Service parks and found an injury incidence of 9.2 nonfatal events per 100,000 visits, with 78 fatalities reported in a 3-year period. Both studies document a low risk of injury but highlight the possible morbidity resulting from wilderness injury and the need for rapid, uniform intervention. Recognition of certain types of injuries can indicate that quick action and/or evacuation is needed. This chapter covers a system for recognizing life threatening trauma. The next four chapters will deal with trauma in specific body areas to include head, neck, chest, and abdomen.

### Establishing Priorities

There are three immediate priorities in managing wilderness trauma:

1. Control oneself. It is normal to feel anxious when confronted with an injured victim. However, anxiety must not be transmitted to the victim or other members of the expedition team. One must be in control of oneself to take control of the situation.
2. Control the situation. The first priority in controlling the situation is ensuring the safety of the uninjured members of the party. Expedient evacuation of a victim requires that all expedition members function at maximal efficiency; even minor injuries to other members in the group can jeopardize physical strength, functional manpower, and the success of the evacuation.
3. Obtain an overview of the situation. The victim's general condition should be evaluated. Is the victim in immediate distress from a condition that requires relatively simple management, such as airway control? Is the victim in such a precarious environmental situation that he or she needs to be moved before resuscitation? Scene security may be integral to the safety of the injured and caregiver. Is the victim properly protected from the elements, including sun, wind, cold, and water?

After the injured person is in stable and safe position, the examiner is ready to implement the Advanced Trauma Life Support (ATLS)-based five steps of wilderness trauma management:

1. Primary survey
2. Resuscitation
3. Secondary survey
4. Definitive plan
5. Packaging and transfer preparation

The purpose of the primary survey is to identify and begin initial management of life-threatening conditions by assessing the following (called the ABCDE of trauma care):

1. *Airway maintenance and cervical spine stabilization*
2. *Breathing*
3. *Circulation, with control of significant external hemorrhage*
4. *Disability: Neurologic status*
5. *Exposure/Environmental control: Completely undress the victim with careful attention to the prevention of hypothermia*

After the primary survey is performed, resuscitation efforts are initiated. The level of resuscitation depends on the equipment and expertise available. At a minimum, resuscitation consists of control of external hemorrhage. In the emergency department, resuscitation would also include the administration of oxygen and intravenous (IV) fluids.

The third step is the secondary survey, a head-to-toe evaluation of the trauma victim that uses inspection, percussion, and palpation techniques to evaluate each of the body's five regions: head and face, thorax, abdomen, skeleton, and skin. A history should be taken at the same time as performance of the secondary survey. The specifics of the mechanism of injury, if unknown to the physician or caregiver, may be of vital importance. Loss of consciousness, head injury, the height of a fall, or the species of attacking animal may influence treatment and evacuation plans, as well as contribute to the stability of the scene. The ATLS AMPLE method of rapid history-taking is a useful way to remember to get the relevant information.

AMPLE stands for the following:

1. Allergies
2. Medications currently used
3. Past medical history/Pregnancy
4. Last meal
5. Event or Environment related to the injury

After this survey, the examining physician should formulate a definitive plan. It is useful to record all observations on paper if the circumstances permit. Such data may prove to be of critical importance to evacuating or hospital personnel.

The first step in formulating a plan is to compile a list of the injuries present. The next step is to determine if any injury warrants evacuation. A determination needs to be made as to the route of evacuation: air, land, or water. Aeromedical evacuation is expensive and, depending on the environment, could pose a risk to both the victim and medical evacuation team. Aeromedical evacuation should be considered only for victims with potentially life- or limb-threatening injuries where the environment allows such a modality.

Packaging the victim for evacuation is the final step. The evacuation effort requires organization, coordination, and great effort on the part of the expedition team. Transfer protocol will be discussed within the respective injury sections.

## Head Injuries

Management guidelines for head injuries in a wilderness setting have not been developed. Effects of head injury can be reduced by means of a protocol that includes early airway control with optimization of ventilation, prompt cardiopulmonary resuscitation, and rapid evacuation to a trauma care facility. Because of the possibility of injury to the spinal column in the neck in head injury, immobilization is critical to prevent further devastating neurologic injury. The focus is next directed to prevention of secondary brain injury. A wilderness head injury protocol allows individuals with widely varying levels of experience and expertise to identify signs of significant head injury, begin proper resuscitation in the context of prevention of secondary brain injury through airway maintenance and circulatory support, and appropriate evacuation. The Glasgow Coma Scale (below) is used to quantify the victim's level of consciousness. This scale evaluates the degree of coma by determining the best motor, verbal, and eye opening response to standardized stimuli.

It is critical that the neurologic assessment be repeated frequently, particularly if evacuation is delayed. Once the airway is secure, resuscitation has been initiated, and the spine immobilized, the victim should be placed in a 30-degree head-up position to assist in control of intracranial pressure by increasing venous outflow. This maneuver should not be attempted if the spine cannot be adequately immobilized. All bleeding from the scalp or face should be controlled with direct pressure. Open wounds, particularly skull fractures, should be irrigated and covered with the most sterile dressing available. Fragments of displaced cranium overlying exposed brain tissue should not be replaced.

The decision to evacuate victims who have sustained closed head injuries can be simplified by dividing the victims into three groups based on probability of injury. The high-risk group is composed of persons with coma score of 13 or less. Focal neurologic signs or evidence of decreasing level of consciousness require evacuation. The low-risk group includes persons who have suffered a blow to the head but are asymptomatic, did not lose consciousness, and complain only of mild headache or dizziness. The group for which the evacuation decision is most difficult is the moderate-risk group. These persons have a history of brief loss of consciousness or change in consciousness at the time of injury, or a history of progressive headache, vomiting, or posttraumatic amnesia. If these signs are present in isolation and the evacuation can be completed in less than 12 hours, the evacuation should proceed. If the evacuation is impossible or will require longer than 12 hours, the victim should be closely observed for 4 to 6 hours. If

the examination improves to normalcy during the observation period, it is reasonable to continue observation.

### Box 18-1. GLASGOW COMA SCALE

This scale evaluates the degree of coma by determining the best motor, verbal, and eye opening response to standardized stimuli.

EYE OPENING	
Spontaneous	4
To voice	3
To pain	2
None	1
VERBAL RESPONSE	
Oriented	5
Confused	4
Inappropriate words	3
Incomprehensible words	2
None	1
MOTOR RESPONSE	
Obeys command	6
Localizes pain	5
Withdraw (pain)	4
Flexion (pain)	3
Extension (pain)	2
None	1
TOTAL	



## Neck Injuries

Injuries to the neck may be classified as blunt or penetrating. Significant blunt injuries include cervical spine injuries and tracheal injuries. Fracture of the larynx and disruption of the trachea usually require surgical intervention unavailable in the wilderness. Victims present with a history of a significant blow to the anterior neck. Physical examination findings include difficulty with speech, air under the skin of the neck and chest, noisy or painful breathing, and acute respiratory distress.

Treatment is focused on establishing and maintaining an airway until evacuation can occur. Injuries of this type can result in significant and progressive swelling, so an airway that is initially open may become compromised with time. If it is not possible to insert a breathing tube, airway maintenance techniques include the chin lift or jaw thrust (if spinal cord injury is possible). In the event lack of availability of intubation with impending hypoxic death, a surgical cricothyroidotomy may be necessary. This involves a stab wound into the neck and placement of a tube in the trachea. It requires understanding of the anatomy of the muscle, cartilage, and blood vessels of the neck. Kits are available for this procedure.

Spinal cord injury, with or without neurological deficits, must be identified in any wilderness multiple trauma victim. The cervical spine, based on its anatomy, is more susceptible to injury than are the thoracic and lumbar spine. Fractures of the cervical spine frequently result in neurologic deficit, with total loss of function below the level of injury. Fractures and dislocations may result in partial or complete neurologic injury distal to the fracture or in no neurologic injury at all. A careful neurologic examination in the field to grade motor strength and to document sensory response to light touch and pinprick yields important information. Motion and strength of motion are evaluated in all extremities. The level and extent of any deficits should be noted for subsequent examinations

When individuals with cervical spine fractures or dislocations are transported, the neck must be stabilized to prevent further injury to the spinal cord or nerve roots at the level of the fracture or dislocation. Approximately 28% of persons with cervical spine fractures have fractures elsewhere in the spine; therefore the entire spine must be protected during transport. Occasionally, a pure flexion event can result in dislocation of one or both of the posterior facets without

fracture or neurologic injury. The victim may complain only of neck pain and limitation of motion. If so, the victim should be transported with the neck rigidly immobilized. With this injury, posterior instability is present, and any further flexion stress could produce a spinal cord injury.

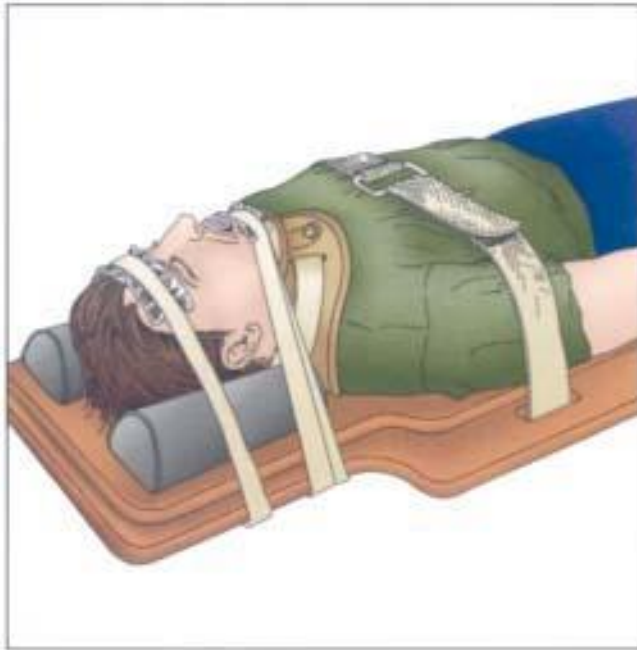After identification of injury, the caregiver faces a critical decision with important ramifications: whether or not to immobilize. Victims who would as a matter of course be immobilized in an urban setting might not be appropriate candidates for immobilization in the wilderness. The decision to immobilize converts an otherwise ambulatory victim who can actively participate in his or her own evacuation to one requiring more involved evacuation procedures. The subsequent evacuation can be dangerous to the victim and rescuers and demands significant expense and resource utilization.

Risk criteria for cervical spine injury and the need for immobilization have been defined. All criteria for the exclusion of immobilization must be satisfied. These include normal mental status without chemical influence; lack of distracting injury; normal neurological examination; and a reliable neck examination without midline neck pain, deformity, or tenderness. Although the need for immobilization poses hazards for the evacuation process, if criteria are met, immobilization takes precedent over ease of evacuation. A difficult balance must be struck in the wilderness between the likelihood of true injury and the danger to the expedition members and rescuers that may ensue when the victim is immobilized.

If a rigid litter is not available, the victim should be maintained on the flattest surface possible. A rigid cervical collar should be placed. All collars allow some degree of movement, particularly rotation. Soft collars offer the least immobilization. Any number of materials may be used to improvise an immobilizing device. Restriction of flexion, extension, and rotation must be achieved to the greatest degree possible. Optimal immobilization consists of a long spine board or litter, rigid collar, bolsters to the sides of the head, and tape or straps restricting movement.

Similar to penetrating head injury, penetrating neck injury is usually due to gun or knife wounds. Most penetrating injuries do not confer bony instability; however, stability should not be assumed. Neurologic deficits, if present, can progress with further movement of an unstable spine. Projectiles should not be removed if embedded in the neck. Penetrating injuries to the neck may not

directly injure the spine, but neurologic sequelae may result from blast effect. The same immobilization criteria should be implemented as when dealing with blunt injuries.



### **Injuries to the Chest**

In the wilderness environment, blunt chest injury usually results from falls or direct blows to the chest. Immediate, life-threatening chest injuries include airway obstruction, tension pneumothorax (air filling the space around the lung), flail chest, and cardiac tamponade (fluid filling the sack around the heart). The hallmark of significant thoracic injury is inability to obtain adequate oxygen, which may sometimes be remedied in the field.

Evaluation begins with visualization and inspection of the chest. The examiner determines if the airway is open and how well air is moving. The pattern of breathing is noted. Immediately following an injury, most trauma victims have rapid breathing, partly from pain and anxiety. Difficulty moving air and the use of accessory muscles of respiration, and retractions, are abnormal and may give clues to an underlying injury. Chest wall movement during respiration should be symmetric. Paradoxical chest wall movement is associated with flail chest. The chest wall should be inspected for contusions and abrasions, which may indicate underlying bone or organ injuries.

After inspection, the chest should be tested for bony tenderness, starting at the ends of the collarbones and working in toward the breastbone. Each rib should be felt individually. Point tenderness over a rib can be associated with contusion

or fracture. Displaced fractures can be felt; occasionally, bone grating can be felt during respiration.

Distention of the neck veins in a person after chest trauma with a heart rate over 130 beats per minute suggests poor blood return to the heart. This may be seen with increased chest or heart pressure such as tension pneumothorax and pericardial tamponade. Significant sternal bruising may herald fracture or cardiac contusion. Subcutaneous air may extend up into the neck and down to the groin. After trauma, subcutaneous air is invariably associated with pneumothorax.

Vocal fremitus describes vibrations transmitted through the chest wall. During speech, the vocal cords emit vibrations in the bronchial air column that are conducted to the chest wall. Diminished vocal fremitus is associated with pneumothorax or hemothorax (blood in the space around the lungs). To test for vocal fremitus, the examiner applies the palm of the examining hand against the person's anterior chest wall. The person is asked to repeat "one, two, three" using the same pitch and intensity of voice with each repetition. If the vibrations are not well perceived, the patient is asked to lower the pitch of the voice. The chest should be symmetric, left to right.

Percussion is used to detect changes in the normal density of an organ.

Percussion of the chest is performed by placing the examining fingertip on the chest wall and sequentially striking the fingertip with the tip of the finger of the other hand. In the trauma victim, dullness replacing resonance in the lower lung suggests hemothorax. Hyperresonance or tympany replacing resonance occurs only with a large pneumothorax or tension pneumothorax.

If a stethoscope is not available, primitive chest auscultation can be performed using a rolled piece of cardboard or paper. Any cylinder that can transmit sound through a column of air accentuates breath sounds when placed against the chest wall. The absence of sounds normally produced by the air movement indicates blockage in the airways or abnormal filtering of sound by fluid surrounding the lung. In the trauma victim, this is invariably associated with pneumothorax or hemothorax.

**Specific Injuries:** The types of injuries that can occur include rib fractures, separation of ribs from the breastbone, fracture of the breastbone, pneumothorax, tension pneumothorax, hemothorax, and flail chest. Rib fractures range in severity from a single fracture, to a major flail segment, which can be associated with an underlying hemopneumothorax and pulmonary contusion. Rib fractures are characterized by painful respiration, most severe on inspiration. Victims often breathe in a characteristically rapid, shallow pattern. Isolated rib fractures

are managed with oral analgesics and rest. Taping and splinting are not necessary or helpful. Inadequate breathing secondary to pain causes most of the difficulty from rib fractures. Deep breathing should be encouraged 10 times hourly to help prevent consolidation of the lung. Victims with multiple rib fractures need to be evacuated as conditions permit. It is difficult to distinguish between a rib fracture and a separation of a rib from the breastbone. With the latter, pain is more likely to be predominantly anterior over the costochondral junction. Pain increases with inspiration and worsens with direct pressure.

A sternal (breastbone) fracture is usually associated with a direct blow to the anterior chest wall. The injury is characterized by severe, constant chest pain that worsens with pressure. Sternal instability is unusual and can be associated with a significant underlying visceral injury, including pulmonary or myocardial contusion. The victim should immediately be evacuated by litter or helicopter.

Simple pneumothorax can occur from an injury that allows air to enter through the chest wall or from an injury to the lung that permits air to escape into the pleural space. Symptoms include rapid breathing, air hunger, one sided chest resonance, absence of breath sounds, and of tactile fremitus. A person with chest pain after chest trauma, particularly with rib fractures, should be suspected of having a pneumothorax.

Treatment of pneumothorax involves decompression of the space around the lung. In the wilderness environment, chest tube insertion is rarely possible. Fortunately, although victims with pneumothorax may complain of chest pain or painful breathing, they are not completely disabled. With analgesia to control pain, ambulation facilitates evacuation. It may be more prudent to set a slow pace with frequent rest periods than to perform an unnecessary litter evacuation. Suspicion of a pneumothorax alone on physical examination does not warrant a catheter or chest tube. When a high index of clinical suspicion is accompanied by incapacitating symptoms, such as shortness of breath, decompression should be considered. The key to saving a victim's life is the understanding that a condition exists that can rapidly progress from a nondisabling condition to a life-threatening condition. Once the diagnosis of pneumothorax is entertained, vigilant observation is necessary in the event of progression to a tension pneumothorax. Symptoms should be closely monitored and frequent repeat examinations should be performed.

A tension pneumothorax develops when a one-way air leak follows lung rupture or chest wall penetration. Air is forced into the thoracic cavity with no means of escape, and pressure mounts within that side of the chest. With increases in pressure, the midline structures are shifted to the opposite side, which impedes

blood return from both the head and body to the heart. Cardiac output is diminished and the victim soon exhibits signs and symptoms of shock. Victims with tension pneumothorax manifest distended neck veins and tracheal deviation away from the side of the lesion. There is unilateral absence of breath sounds, and that side of the chest is hyperresonant or tympanic. Tension pneumothorax is life-threatening and frequently associated with additional serious injuries. It mandates rapid chest decompression, followed by evacuation to a medical facility.

Decompression is performed by inserting a needle or catheter into the chest and converting the tension into an open pneumothorax. Ideally, a 14-gauge catheter is inserted through the skin over the second rib in the mid-clavicular or anterior axillary line. Once the rib is identified with the tip of the needle, the needle is marched over the upper surface of the rib and inserted through the muscles and pleura into the chest cavity. As the pressure within the chest is released, a distinct rush of air is heard. The plastic catheter is advanced over the tip of the needle, the needle withdrawn, and the catheter left in place to ensure continued decompression. The needle should not be reintroduced into the catheter because it may damage or sever the catheter. Because tension pneumothorax is commonly associated with severe injury, the victim should be evacuated as rapidly as possible. A rubber glove or a finger cot can be attached to the external catheter opening to create a unidirectional flutter valve that allows air to exit from the pleural space.

If resources are limited and treatment is needed, any number of devices can be used to decompress the chest. A sharp instrument and hollow tube, sterilized as well as possible, are all that is needed. Rapid cleansing of the skin surface is accomplished with antiseptic, alcohol, or water. A Heimlich valve kit is ideal for decompression and represents a valuable addition to the expedition first aid arsenal. A tube open to the atmosphere can accomplish decompression. The end of the tube can be covered with a rubber glove, finger cot, or plastic bag; one-way flow evacuating the chest is the goal. It must be emphasized that this procedure is not without morbidity and should only be used by trained personnel under optimal conditions. Antibiotics with gram-positive coverage should be initiated if the pleural space is penetrated with an indwelling catheter or tube.

Hemothorax is usually associated with multiple rib fractures resulting from a direct blow to the chest. The primary cause of a hemothorax is laceration of the lung or of vessels inside the chest. The victim complains of chest pain, tenderness associated with rib fractures, inspiratory pain, and inadequate breathing. Vocal fremitus is absent, percussion may be flat or dull, and breath sounds are diminished or absent. A chest tube may be placed if proper equipment is

© 2005 Sally Schindele, MD

available and evacuation may be delayed. Needle aspiration of a hemothorax is unnecessary in the immediate postinjury period and may precipitate a pneumothorax. As in the case of pneumothorax, treatment is strictly based on clinical deterioration. Isolated hemothorax from blunt trauma leading to shock is unusual and commonly associated with other massive injuries.

When three or more ribs are fractured in both the front and back, a portion of the chest wall may be unstable. As negative pressure develops during inspiration, this segment paradoxically moves inward and inhibits ventilation. A flail segment indicates a severe direct blow to the chest wall with associated multiple rib fractures and decreased lung volumes, often with associated underlying lung contusion. The contusion can be expected to progressively impair ventilation and oxygenation over the succeeding 48 hours. Victims will often tolerate a flail segment for the first 24 to 48 hours, after which they require mechanical ventilation.

Any victim with a flail segment should be rapidly evacuated. Because the victim is usually incapable of participating in evacuation, a litter should be prepared or aeromedical evacuation considered. Restrictive external chest wall supports, including taping or extensive stabilization with sandbags, are not indicated. These measures hinder chest wall movement and decrease lung volume. However, cushioning of the flail segment to control unnecessary motion and pain may provide minimal relief of discomfort.

Blunt cardiac injuries leading to pericardial tamponade or cardiac contusion are rare. Pericardial tamponade is life-threatening. The pericardial sac is fibrous and expands little. A small amount of intrapericardial blood can restrict heart function. Blunt injury causing tamponade is usually from chamber rupture and rarely survivable, particularly in a remote setting. Once pericardial tamponade is diagnosed, immediate evacuation is required. Treatment consists of median sternotomy in a hospital operating room. The only temporizing measure pending evacuation is pericardiocentesis. This procedure can be lifesaving, particularly if a cardiac injury with a slow leak exists. However, its application in the wilderness setting should occur only if there is a high index of suspicion, coupled with shock and impending death unresponsive to resuscitative efforts. A long (approximately 15 cm) 16- to 18-gauge needle with an overlying catheter is introduced through the skin 1 to 2 cm below and to the left of the tip of the breastbone. The needle is advanced at a 45-degree angle with the tip directed at the left shoulder blade. When the pericardial sac is entered, aspiration with a syringe follows. The catheter is left in place and secured for possible repeat aspirations as the victim's condition warrants. Immediate evacuation should follow.

## Injuries to the Abdomen

Intraabdominal injuries in the wilderness setting are unique because they are often difficult to recognize. *However, once recognized or suspected, all intraabdominal injuries require rapid resuscitation and immediate evacuation.* The abdomen represents the most frequent site of life-threatening hemorrhagic shock; however, in the wilderness setting, few diagnostic and treatment options exist. Injuries can be classified as blunt or penetrating.

Blunt intraabdominal injury can be caused by falls, by heavy objects, or induced by equines. In the wilderness we need to be aware of the potential for intraabdominal bleeding as an occult injury. Penetrating intraabdominal injuries may result from gunshot, stab, or arrow wounds. Low-caliber gunshot injuries often present with small entrance and no exit wounds. High-caliber, high-velocity gunshot injuries may have relatively innocuous entrance wounds but may be associated with large, disfiguring exit wounds and extensive internal injuries. Shotgun injuries have potentially lower incidence of underlying visceral injury than gunshot wounds, but there is often extensive damage. The potential exists for delayed development of infection from a single penetrating pellet to the intestine. In stab wounds the penetrating object is usually a knife or arrow, but may include tree limbs. Any deep skin laceration from the nipple line to the groin should be considered to have damaged an intraabdominal organ. The odds of an abdominal gunshot wound injuring a visceral organ exceed 95%, with a stab wound this is from 50% to 60%.

For descriptive purposes, the abdomen may be divided into thoracic, true, and retroperitoneal compartments. The thoracic abdomen contains the liver, spleen, stomach, and diaphragm. The liver, spleen, and — more rarely — stomach may be injured by direct blows to the ribs or sternum. Twenty percent of persons with multiple left lower rib fractures have a ruptured spleen. A direct blow below the sternum may result in increased intraabdominal pressure with subsequent rupture of the liver or diaphragm. The true abdomen contains the small bowel, large bowel, and bladder. Isolated bowel injuries are rare in the wilderness setting. Blunt bladder or rectal injury usually occurs in conjunction with severe pelvic fracture and carries high mortality. The retroperitoneal abdomen contains the kidneys, ureters, pancreas, and great vessels. It is notoriously difficult to evaluate by physical examination. Life-threatening hemorrhage can occur into the true abdomen or the retroperitoneal space.



The examiner should look for signs of early shock: 1) rapid, weak, or thready pulse, 2) rapid breathing, 3) cool or clammy skin, with delay in return to normal color after pressure is applied. The examination of the abdomen begins with a visual inspection. Contusions and abrasions may be the only signs of occult visceral injury. Abdominal swelling due to bleeding is a very late sign and never present before shock. Abdominal inspection should survey the flanks, lower chest, and back. Inspection of the back is done after feeling along the spine while the victim is supine. The victim should be very carefully logrolled if there is any suspicion of spinal injury.

Looking for muscle guarding, the examiner gently palpates the abdomen in all four quadrants. Any persistent guarding or tenderness after wilderness trauma mandates rapid evacuation. Percussion tenderness is an indicator of peritoneal irritation, also mandating evacuation. The presence or absence of bowel sounds has little prognostic significance. Bowel sounds may be present in the face of significant intraabdominal hemorrhage or, conversely, absent in victims when extraabdominal injuries induce ileus.

Referred pain to the left shoulder strongly suggests the presence of a ruptured spleen. This pain is often exaggerated by placing the victim's head and chest lower than the hips, increasing the amount of left upper quadrant blood irritating the diaphragm. Pain from the retroperitoneal abdomen associated with injuries to the kidney or pancreas may be referred to the back. However, referred pain is usually a late finding and not helpful in the evaluation of acute trauma.

Blood in the urine that does not clear quickly or with an associated injury, such as pelvic fracture or abdominal or back pain, requires immediate evacuation. To minimize blood loss, the victim should be kept stationary and the evacuation team brought as close to the victim as possible.

Occasionally, a close-range shotgun blast results in a soft tissue defect large enough for the injured bowel to extrude through the wound. The injured bowel should not be placed back into the abdomen. Since evacuation is often delayed in the wilderness, it is better to have fecal contents outside, rather than inside, the peritoneal cavity. The exteriorized bowel should be kept moist and covered at all times. Uncovered bowel outside the peritoneal cavity rapidly desiccates and dies. Exposed bowel should be covered with an abdominal pack or cloth moistened with sterile saline at best, or at worst with potable water. The dressing should be checked and remoistened at least every 2 hours.

Although no data exist addressing the management of stab wounds in the wilderness environment, the following approach is practical and reasonable. If the wound extends into the subcutaneous tissue, the evacuation decision depends on local wound exploration. This procedure is simple to perform, even in the wilderness environment if there is a supply of local anesthetic and sterile gloves in the medical kit. The skin and subcutaneous tissue are infiltrated with local anesthetic, and the laceration is extended several centimeters to clearly visualize the underlying anterior fascia. It is helpful to use lidocaine 1% with epinephrine to minimize slight but annoying bleeding that can impair visualization. The wound should never be probed with any instruments, particularly if overlying the ribs.

Wound exploration is confined to the area from the costal margin to the inguinal ligament. Local wound exploration is contraindicated in wounds that extend above the costal margin, because it is possible for such exploration to communicate with a small pneumothorax, potentially exacerbating respiratory distress.

If thorough exploration of the wound shows no evidence of anterior fascial penetration, and if the victim demonstrates no evidence of peritoneal irritation, the wound can be closed with tape (Steri-Strips) or adhesive bandages, dressed, and the evacuation process delayed. Physical examination should be performed every few hours for the next 24 hours. If no peritoneal signs develop and the victim feels constitutionally strong, a remote expedition may resume with caution and an eye to evacuation should the victim become ill.

In the wilderness environment, it is prudent to have a low threshold for evacuation because of technical difficulties in performing wound exploration—such as insufficient light and inadequate instruments. Persons who have been impaled by long objects, such as tree limbs or ski poles, should have the object left in place, and carefully shortened, if possible, to facilitate transport.

## TRANSPORT OF VICTIMS

There is very little specific literature available on the use of equines to transport ill or injured persons. However, general information can be adapted to incorporate the use of stock in these situations. Factors to consider in moving a person are listed below.

## EVACUATION SIZE-UP FACTORS

What are the scope and the magnitude of the overall situation?

Are there immediate life-threatening hazards?

What is the location, and how many victims are there?

What is the patient's condition? Is the subject able to assist rescuers?

- a. No injury (able to walk unassisted)
- b. Slight injury (able to walk unassisted)
- c. Slight injury (assistance required to walk)
- d. Major injury (requires considerable attention and assistance)
- e. Deceased

Is there a need for technical rescue?

Is the scene readily accessible?

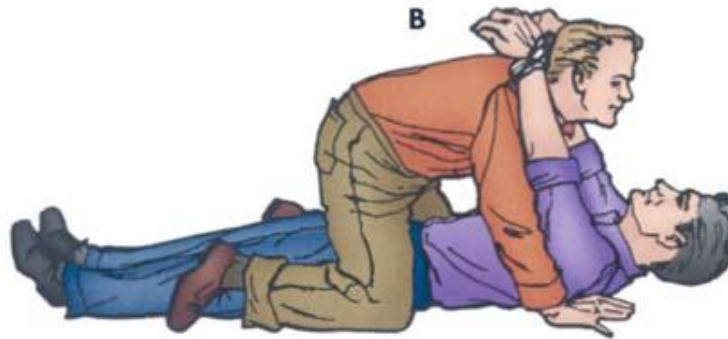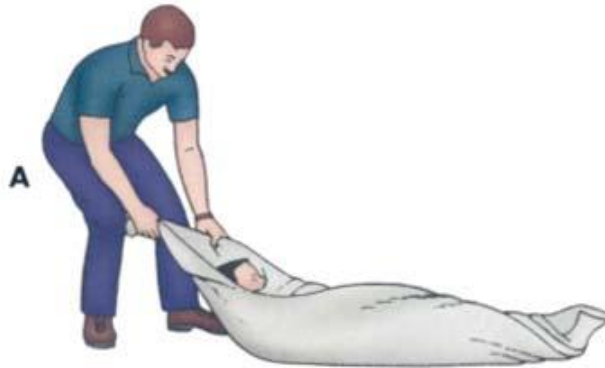What rescue resources (including rescuers and equipment) are available?

How far must the patient (or patients) be transported?

Are ground or air transport assets available?

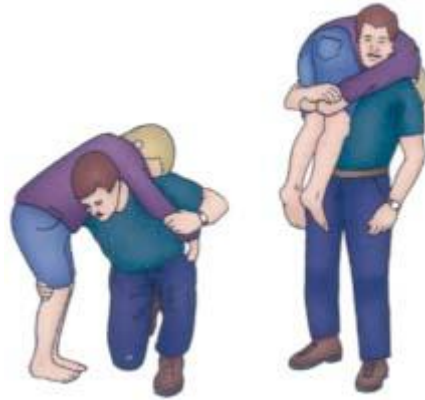The most expedient method of transporting an ill or injured person is by dragging or carrying them. Although these methods of transportation are not ideal and may not meet standard care criteria, the urgency of the situation may outweigh the risks involved. In addition, the process can be physically demanding, and rescuers can quickly become fatigued to the point of hazard. Therefore other options often should be considered before a victim is moved, especially a long distance. A drag or carry may be the best option when a person cannot move under his or her own power, injuries will not be aggravated by the transport, resources and time are limited, the travel distance is short, or the terrain makes the use of multiple rescuers or bulky equipment impractical. A "blanket drag" (**A**) can be performed on relatively smooth terrain by one or more rescuers rolling the victim onto a blanket, a tarp, or even a large coat and pulling it along the ground. This simple technique is especially effective for rapidly moving a person with a spinal injury to safety because the victim is pulled along the long axis of the body. In extreme circumstances the "fireman's drag" (**B**) can be used. In this type of drag the rescuer places the bound wrists of the victim around his or her neck, shoulders, or both and crawls to safety.

*(From Auerbach PS: Medicine for the outdoors: the essential guide to emergency medical procedures and first aid, ed 3, New York, 1999, Lyons Press.)*

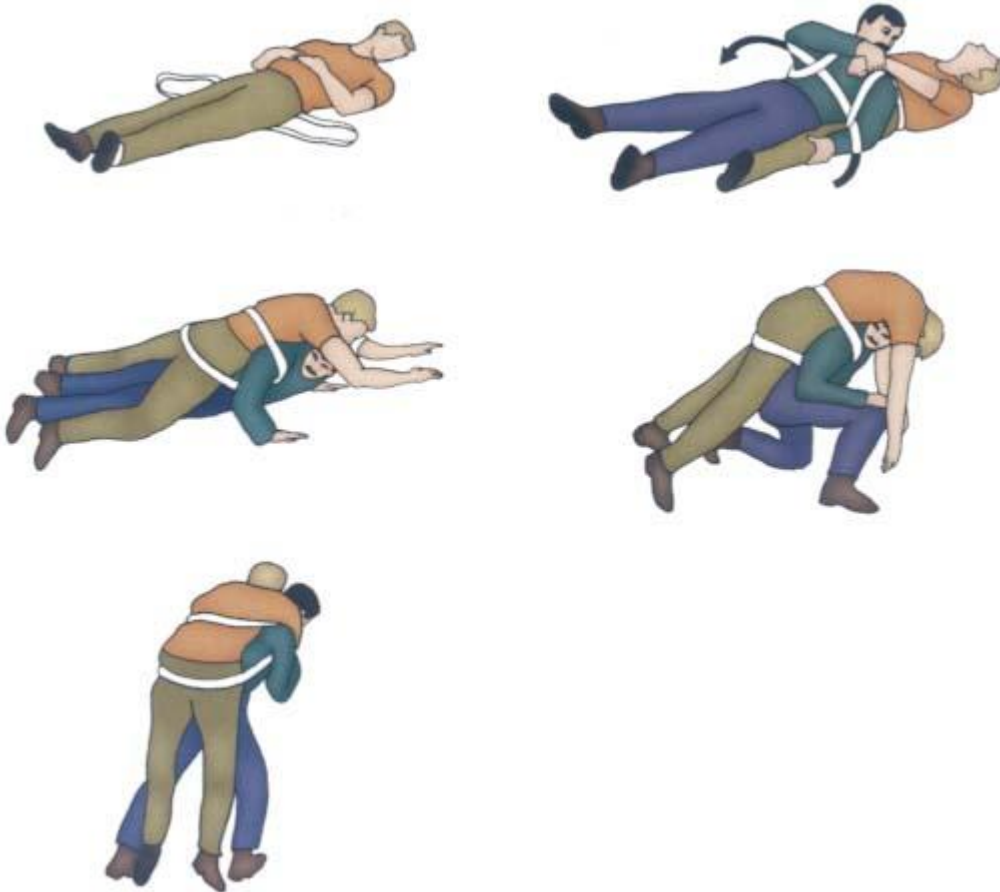


A carry should be considered only after it is confirmed that the victim cannot assist rescuers or travel on his or her own. Beyond simply lifting a person over one's shoulder in a "fireman's carry" or acting as a human crutch, a more efficient one-person carry can be accomplished by using equipment, such as webbing, coils of rope, or commercial harnesses. Equipment-assisted carries are particularly effective for moving a victim across a short distance over rough terrain or when a person must be quickly removed from a hazardous environment. In the simplest equipment-assisted carry, 15 to 20 feet of webbing is wrapped around the victim, who is "worn" like a backpack by the rescuer.

*Classic fireman's carry: The rescuer must use his or her legs for lifting. (Ibid.)*

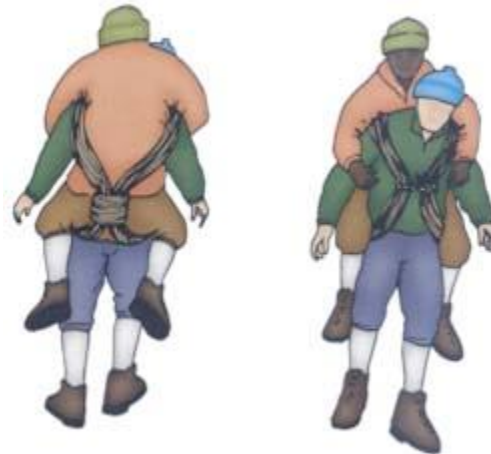

*Web sling (tied into a loop) used to carry a victim. The rescuer must use his or her legs for lifting*

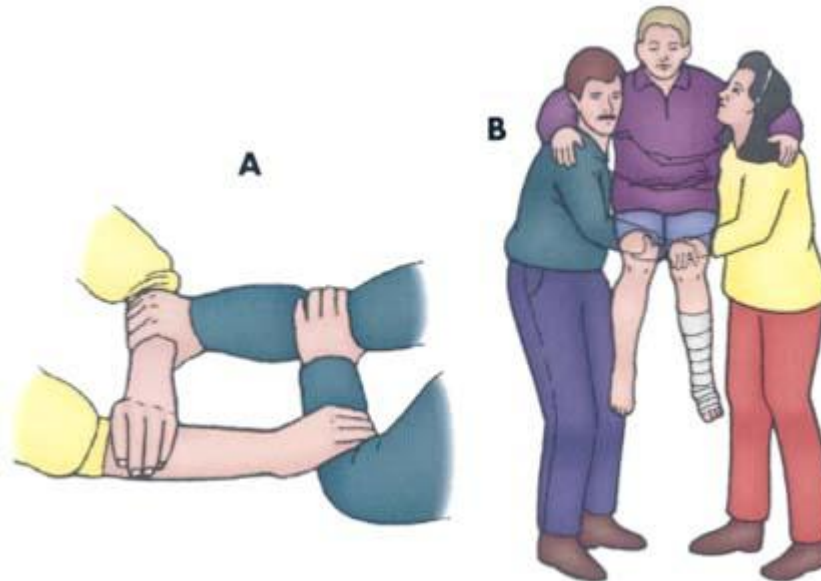


*Backpack carry.*



*Single-rescuer split coil carry.*

If two rescuers are available, additional and often superior options for carrying a victim become possible. One option consists of two rescuers forming a seat by joining their hands or arms together (**A**). The victim sits on the "platform" and holds on to the rescuers for support. It is difficult to cover a long distance or rough terrain when using this technique. **B** shows an alternative four-handed seat that helps support the victim's back. (*Ibid.*)

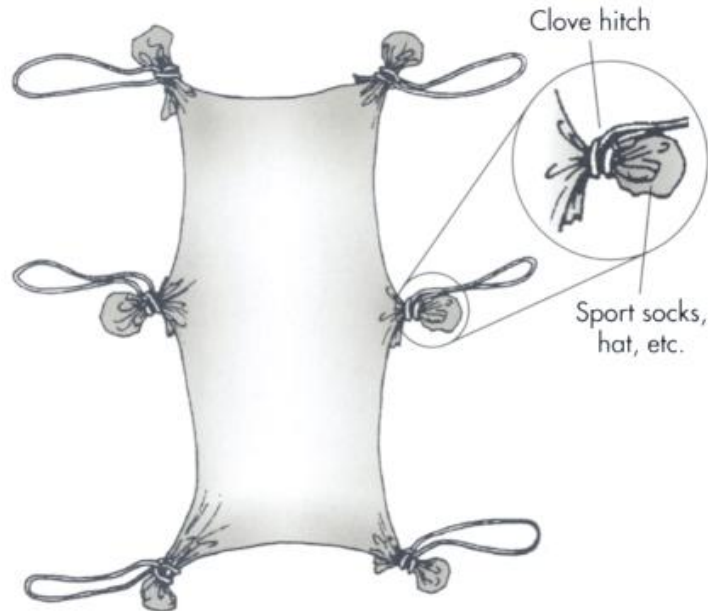


A coil of climbing or rescue rope can be used to form a "two-rescuer split coil seat," with each rescuer slipping a side of the rope coil around his or her outside shoulder. The patient then sits on the "seat" formed by the rope. This approach requires gentle terrain without narrow trails.

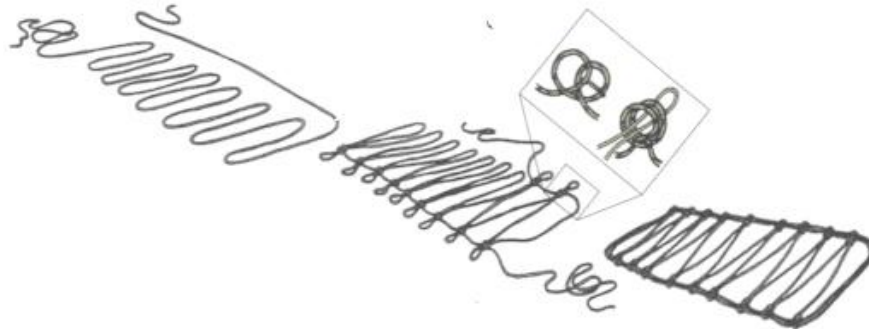


### **LITTER IMPROVISATION**

The simplest improvised **litter** is made from a heavy plastic tarpaulin, tent material, manti or large polyethylene bag. By wrapping the material around a rock, wadded sock, or glove and securing it with rope or twine, the rescuer can fashion handles in the corners and sides to facilitate carrying. The beauty of this device is its simplicity, but it can be fragile, so care must be taken not to exceed the capability of the materials used. As an additional precaution, all improvised **litters** should be tested with an uninjured person before being loaded with a victim. This type of soft **litter** can be dragged over snow, mud, or flat terrain but should be generously padded, with extra clothing or blankets placed beneath the victim.

*Improvised handled soft stretcher.*

A coil of rope also can be fashioned into a **litter**, called a *rope litter* or *clove hitch stretcher*, with a 150 to 200 foot rope. The rescuer constructs the **litter** by laying out 16 180-degree loops of rope (8 on each side of center) across an area the desired width of the finished **litter**. The running ends of the rope are used to tie a clove hitch around each of the loops, and then the unused portion of rope can be passed through the loops on the other side and tied off. The **litter** is then padded with clothing, sleeping pads, and similar material. Lateral stability can be added by tying poles to the finished product. Because of its nonrigid construction, this **litter** offers little back support and is best suited for victims with injuries that do not require immobilization.



A sturdy blanket, manti, or tarp can be used in combination with stout tree branches. The cloth is stretched over the top of two poles, which are held about 3 feet apart; tucked around the far pole; and folded back around the other pole. The remaining material lies over the first layer to complete the **litter**. The weight of the victim holds the blanket in place.



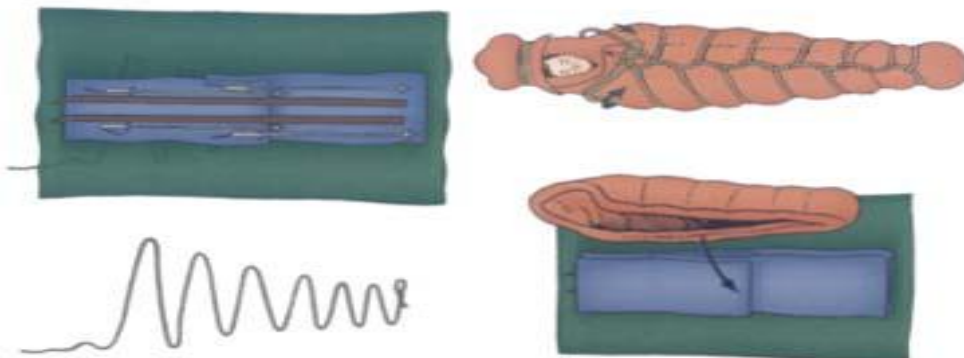
*Improvising a stretcher from two rigid poles and a blanket, manti, or tarp.*



It may be necessary to transport victims with certain injuries (i.e., spine injuries; unstable pelvis, knee, or hip dislocations) on a more rigid **litter**. Stout tree limbs can provide a rigid support framework for such a device. Sturdy branches then can be fastened to the framework for use as carrying handles, and the platform can be padded with ground pads, sleeping bags, or a similar material.

Combining a rope **litter** with a rigid **litter** can provide more strength and versatility. The rescuer fashions this type of **litter** by first building a platform of poles or limbs, using a blanket as in a rigid **litter**, and placing the victim in a sleeping bag on the platform. The patient and platform are wrapped and secured with a length of rope. Although this type of **litter** offers improved support, strength, and thermal protection, careful thought must be given to the physical and psychological effects such a restrictive enclosure may have on the victim.

*Mummy litter. (Ibid.)*



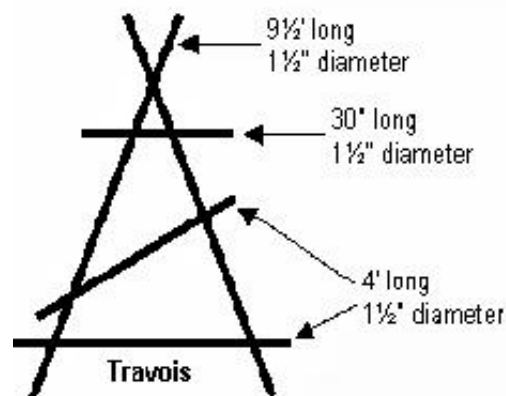
If long distances must be traveled or if suitable pack animals are available, a **litter** may be constructed so that it can be dragged or slid along the ground like a sled. One such device is known as a *sledge*. This **litter** is fashioned out of two forked tree limbs, with one

© 2005 Sally Schindele, MD

side of each fork broken off. The limbs form a pair of sled-like runners that are lashed together with cross members to form a patient platform. The sledge offers a solid platform for victim support and stabilization. If sufficient effort is put into fashioning a smooth, curved, leading edge to the runners, a sledge can be dragged easily over smooth ground, mud, ice, or snow. Ropes also can be attached to the front of the platform for hauling and to the rear for use as a brake when traveling downhill.



A travois is a similar device that is less like a sled and more like a travel trailer (without wheels). A travois is a V-shaped platform constructed out of sturdy limbs or poles that are lashed together with cross members or connected with rope or netting. The open end of the V is dragged along the ground, with the apex lashed to a pack animal or pulled by rescuers. Although the travois can be dragged over rough terrain, the less smooth the ground, the more padding and support necessary for comfort and stabilization. A long pole can be passed through the middle of the platform and used for lifting and stabilization by rescuers when rough terrain is encountered.



When victims are transported in improvised **litters**, especially over rough terrain, they should be kept in a comfortable position, with injured limbs elevated to limit pressure and movement. To splint the chest wall and allow full expansion of the unaffected lung,

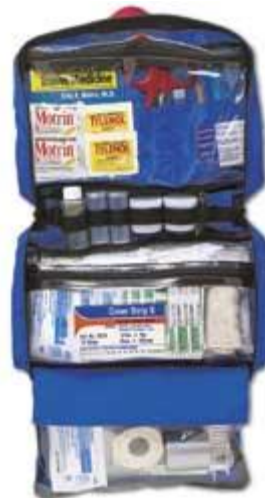victims with chest injuries generally should be positioned so that they are lying on the injured side during transport. For a person with a head injury, the head should be elevated slightly, and for persons with breathing problems or heart attack the upper body should be elevated. Conversely, when the victim is in shock the legs should be elevated and the knees slightly flexed. Whenever possible, unconscious patients with unprotected airways should be positioned so that they are lying on their side during transport to prevent aspiration.

When a victim dies on the trail and transport is delayed, the person should be placed over a rock or tree trunk in the position that s/he will be carried on a single pack animal. Otherwise it will be difficult to pack the body out after *rigor mortis* has set in.

### **MEDICAL KITS**

Each individual should carry a small saddle bag size medical kit which has been customized to include their personal medications (such as bee sting kits for those at risk). These are commercially available as kits for backpackers. The group medical kit should contain a more extensive inventory of supplies and drugs. Additional items should be added for evaluation of injury. This would such items as a stethoscope. Dermabond and broad spectrum antibiotics should be included as well. Several dental repair kits can be added. My personal choice at this time is the Back Country Medical Kit by Adventure Medical. It is designed for week-long adventures. Includes a wound management module with supplies used in hospital emergency rooms, a Sam Splint, a hypo/hyperthermia thermometer, a wide assortment of meds, splinter forceps, and Mountaineers First Aid Manual. It weighs 2 lbs and this description is from Wyoming Outdoor Industries, Inc.

Item # 172BC



## IMPROVISING TOOLS FOR MEDICAL EMERGENCIES

There are a number of items that you will carry into the backcountry which can be used to improvise medical emergency equipment. Uses of some of these will not be immediately obvious, and there are some without which it will be difficult to improvise. However, a little foresight and preparation make improvisation much easier. Efficiency translates into speedy preparation and assembly, which ultimately results in better care. The following section lists items that facilitate improvisation in the field (Auerbach: *Wilderness Medicine*, 4th ed., Copyright © 2001 Mosby, Inc.).

### **Knife**

The knife can be a fairly simple model, but it should have an awl for drilling holes. The awl on a Swiss Army knife works quite well for this purpose. This allows you to create well-fitted components during improvisation (e.g., a drilled cross-bar attached to ski tips for an improvised rescue toboggan).

### **Tape**

Carry some form of strong, sticky, waterproof tape. (This item *cannot* be improvised.) Use either cloth adhesive tape (already in the medical kit) or duct tape. Duct tape is ideal for almost all tasks, even being useful on skin when needed (e.g., to close wounds, treat blisters, or tape an ankle). Some persons may be sensitive to the adhesive. Fiberglass strapping tape has greater tensile strength and is ideal for joining rigid components. However, it is less sticky than duct tape and not as useful for patching torn items. Extra tape can be carried by wrapping lengths of it around pieces of gear.

**Plastic Cable Ties**

Lightweight cable ties can be used to bind almost anything together (for example, binding pack frames together for improvised litters or ski poles together for improvised carriers). They are also perfect for repairing many items in the backcountry.

**Parachute Cord** has hundreds of uses in the backcountry. It can be used for trucker's hitch traction and for tying complex splints together. Parachute cord is light; carry a good supply.

**Safety pins** have various uses.

- Using two safety pins to pin the anterior aspect of the tongue to the lower lip to establish an airway in an unconscious victim whose airway is obstructed
- Replacing the lost screw in a pair of eyeglasses to prevent the lens from falling out
- Improvising glasses: Draw two circles in a piece of duct tape where your eyes would fit. Use the pin to make holes in the circles, then tape this to your face. The pinholes will partially correct myopic vision and protect the eyes from ultraviolet radiation. Slits can also be used for improvised sunglasses.
- Neurosensory skin testing
- Puncturing plastic bags for irrigation of wounds
- Removing embedded foreign bodies from the skin
- Draining an abscess or blister
- Relieving a subungual hematoma
- As a fishhook
- As a finger splint (mallet finger)
- As a sewing needle, using dental floss as thread
- Holding gaping wounds together
- Replacing a broken zipper
- Holding gloves or mittens to a coat sleeve
- Unclogging jets in a camping stove
- Pinning triage notes to multiple victims
- Removing a corneal foreign body (with ophthalmic anesthetic)
- In a sling and swath for shoulder or arm injuries
- To extract the clot from a thrombosed hemorrhoid
- To pin a strap or shirt tightly around the chest for rib fracture support
- Tick removal

**Wire**

Braided picture-hanging wire works well because it is supple and ties like line. Its strength makes it superior for repairing and improvising components under an extreme load, such as fabricating improvised rescue sleds or repairing broken or detached ski bindings.

**Bolts and Wing Nuts**

Bolts and wing nuts make the job of constructing an improvised rescue sled much easier (see *Improvised Rescue Sled* or *Toboggan* section). Bolts are useful only if holes can be created to put them through. Therefore a knife with an awl is needed for drilling holes.

**Prefabricated Cross-Bar**

The prefabricated cross-bar can be used for double traction splint systems. A cross-bar is easily fabricated from a branch, but carrying a prefabricated device, such as a 6-inch predrilled ski pole section, saves time.

**Ensolite (Closed-Cell Foam) Pads**

Since the introduction of Therm-a-Rest types of inflatable pads, closed-cell foam has become increasingly scarce; however, closed-cell foam (Ensolite) is still the ultimate padding for almost any improvised splint or rescue device. The uses for closed-cell foam are virtually unlimited. Even die-hard Therm-a-Rest fans should carry a small amount of closed-cell foam, which is lightweight and doubles as a comfortable seat cushion. Furthermore, unlike inflatable pads, Ensolite will not puncture and deflate.

Therm-a-Rest pads also have their place, being useful for padding for long bone splints and immobilizers (e.g., an improvised universal knee immobilizer). An inflatable pad can also be used to cushion pelvic fractures. First, wrap the deflated pad around the pelvis.

Then secure the pad with tape and inflate it, creating an improvised substitute for military anti-shock trousers (MAST device).

**Fluorescent Surveyor's Tape**

Surveyor's tape can be used much like Hansel and Gretel's bread crumbs to help relocate a route into or out of a rescue scene. It is also ideal for marking shelters in deep snow and can serve as a wind sock during helicopter operations on improvised landing zones. Surveyor's tape is not biodegradable, so it should always be removed from the site after the rescue is completed.

**Space Blanket or Lightweight Tarp**

For improvising hasty shelters in times of emergency, some form of tarp is essential. In the snow a slit trench shelter can be built in a matter of minutes

using a tarp. Otherwise, the complex and time-consuming construction of improvised structures such as snow caves, igloos, or tree branch shelters might be necessary. Typically, little time or help is available for this task during emergencies. In addition, tarps are essential for "hypothermia wraps" when managing injured persons in cold or wet conditions. The only advantage of a space blanket over other tarps is its small size, which means there is a good chance it was packed for the trip.

**REFERENCES:**

Auerbach, Paul S., editor: Wilderness Medicine 4<sup>th</sup> Edition; C.V. Mosby, St. Louis, MO; 2004.

Auerbach PS, Donner HJ, Weiss EJ: Field Guide to Wilderness Medicine 2<sup>nd</sup> Edition; C.V. Mosby, St. Louis, MO; 2003.

Forgey, William W., editor: Wilderness Medical Society Practice Guidelines for Wilderness Emergency Care 2<sup>nd</sup> Edition; The Globe Pequot Press, Guilford, CN; 2001.